

CASE REPORT

ERCP performed
with a single-use
duodenoscope

STENT AND STONE REMOVAL IN A PATIENT WITH RARE ANATOMICAL VARIATION OF THE CYSTIC DUCT

Prof. Dr. med. Jörg Schirra

LMU Klinikum München
Medizinische Klinik
und Poliklinik II
Campus Groß-Hadern,
Germany

Prof. Dr. med. Christian Lange

LMU Klinikum München
Medizinische Klinik
und Poliklinik II
Campus Groß-Hadern,
Germany

Dr. med. Alexander Philipp

LMU Klinikum München
Medizinische Klinik
und Poliklinik II
Campus Groß-Hadern,
Germany

PATIENT HISTORY

An 85-year-old female patient presented with choledocholithiasis, cholecystolithiasis and extra hepatic biliary cholestasis (no cholangitis). Choledocholithiasis with multiple bile duct stones was diagnosed by endoscopic ultrasound. During a first ERCP, partial stone removal (multiple stones up to 6 mm) was possible after biliary sphincterotomy. An 11.5 F and 5 cm plastic stent was placed. Cholestasis parameters normalized after the procedure.

PROCEDURE

Three days after the first procedure, a second ERCP was performed using Ambu® aScope™ Duodeno, a single-use duodenoscope. Navigation to the descending part of the duodenum and the papilla was easily achieved using the duodenoscope. Cannulation could be achieved quickly (~1 min) in the first attempt, and the previously placed plastic stent (11.5 F) was removed using a snare.

The cholangiography showed an 8 mm stone in the central right hepatic duct (Figure 1).

No stones were visible within the common bile duct. Stone extraction from the dilated central hepatic duct failed with a basket but succeeded with a balloon catheter.

Balloon occlusion cholangiography with contrast filling of the gallbladder revealed an abnormal confluence of the central right hepatic duct and the cystic duct (Figure 2).

This constitutes a rare anatomical variation (< 2 %; see Choi et al., 2003).

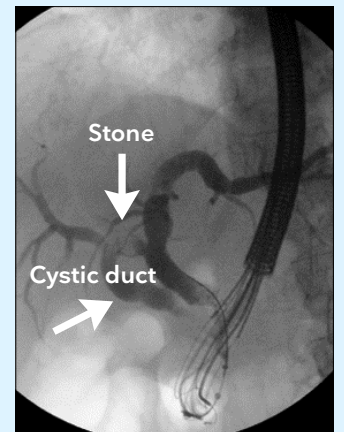


Figure 1: Fluoroscopy showing stone within the central right hepatic duct.

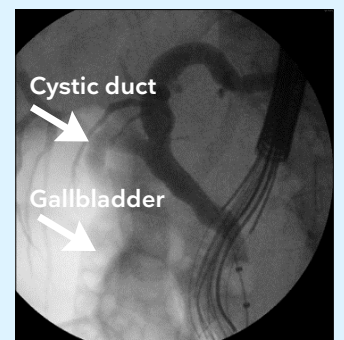


Figure 2: Fluoroscopy showing gallbladder and abnormal confluence of the central right hepatic duct and the cystic duct.

CASE REPORT

ERCP performed
with a single-use
duodenoscope

The abnormally draining cystic duct contained two more stones, each of them approx. 6 mm in diameter (Figure 3).

The balloon catheter was advanced through the cystic duct into the gallbladder aided by guide wire, but attempts at stone removal failed. The stones were then pushed into the gallbladder by flushing the cystic duct with saline.

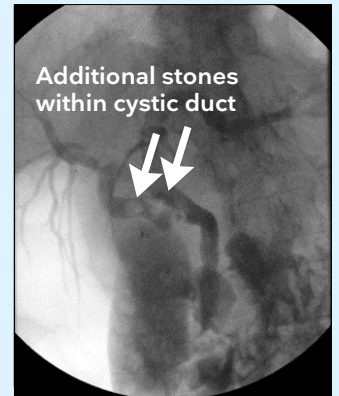

Figure 3: Fluoroscopy showing additional stones within the abnormally draining cystic duct.

OUTCOME

Indication for cholecystectomy because of very high risk of recurrence of choledocholithiasis. The surgeon responsible was informed of the anatomical variation (abnormal confluence of right hepatic duct and cystic duct) to avoid complications.

CONCLUSION

Endoscopists should be aware of anatomical variations of intrahepatic bile ducts, even though confluence of the right hepatic duct and the cystic duct is rare.

The Ambu® aScope™ Duodeno was useful for guidewire-assisted cannulation and stone removal in this unexpected case.

REFERENCES

Choi JW, Kim TK, Kim KW, Kim AY, Kim PN, Ha HK, Lee MG. Anatomic variation in intrahepatic bile ducts: an analysis of intraoperative cholangiograms in 300 consecutive donors for living donor liver transplantation. Korean J Radiol. 2003 Apr-Jun;4(2):85-90. doi: 10.3348/kjr.2003.4.2.85. PMID: 12845303; PMCID: PMC2698075

Ambu

Ambu A/S
Baltorpbakken 13
2750 Ballerup
Denmark
Tel.: +45 7225 2000
ambu.com